



STUDY OF LANGUAGE-RELATED WHITE MATTER TRACT CONNECTIONS IN SCHIZOPHRENIA USING DIFFUSION STOCHASTIC TRACTOGRAPHY



J.L. Alvarado, D.P. Terry, D. Markant, T. Ngo, R. Kikinis, C.F. Westin, R.W. McCarley, M.E. Shenton, M. Kubicki

Psychiatry Neuroimaging Laboratory, Brigham and Women's Hospital, Harvard Medical School -- Clinical Neuroscience Division, Laboratory of Neuroscience, Boston VA Health Care System-Brookton Division, Department of Psychiatry, Harvard Medical School -- Surgical Planning Laboratory, MRI Division, Department of Radiology, Brigham & Women's Hospital -- Laboratory of Mathematical Imaging, Department of Radiology, Brigham & Women's Hospital -- Computation and Cognition Lab, Department of Psychology, New York University

BACKGROUND

Language and verbal memory deficits are among the most striking in schizophrenia (Saykin et al., 1991, 1994; Adams et al., 1993; Kareken et al., 1996; Nestor et al., 1997). Functional studies have also shown abnormal activation in frontal and temporal cortices during linguistic tasks (Yurgelun-Todd 1996, Stevens et al., 1996, Ragland et al., 2001, Heckers et al., 1998).

Many theories point to connection faults between these regions, namely Broca's and Wernicke's areas (Crow 1998; Ford et al., 2002). These connection faults are thought to be accounted for by neuroanatomical abnormalities in white matter in schizophrenia. We chose to explore these areas, specifically the inferior frontal gyrus (IFG) and the superior temporal gyrus (STG), and their connections travelling through the arcuate fasciculus and the inferior occipito-frontal fasciculus (IOFF) (see Figure 1).

Diffusion Tensor Imaging (DTI) is a relatively new tool used to investigate white matter tracts because of its ability to distinguish between tissue types by characterizing water diffusion. Extraction and measurement of these white matter tracts, however, remains technically challenging. By using our novel method of stochastic tractography using DTI scans acquired at our facilities, we sought to recreate and investigate the arcuate fasciculus and IOFF in schizophrenia.

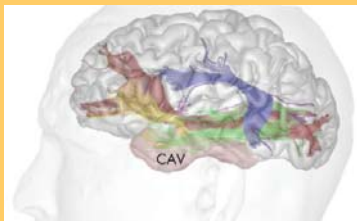


Figure 1. (above) Model of language networks proposed by Mandonnet (2007) and Duffau (2008), involving dorsal (arcuate fasciculus, blue) and ventral (IOFF, red) processing streams

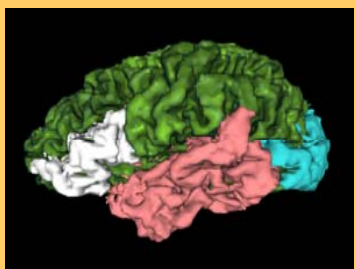


Figure 2. Automatically extracted ROIs of the IFG (white), STG (pink), and the occipital lobe (teal).

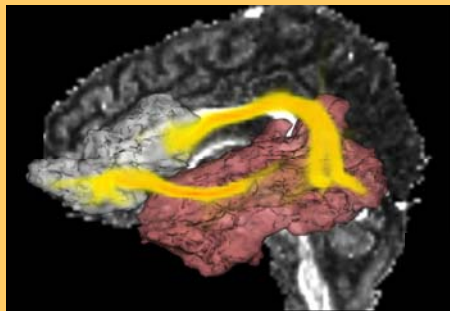


Figure 4a. (above) Connections extracted by stochastic tractography between IFG (white) and STG (pink), overlaid on FA map

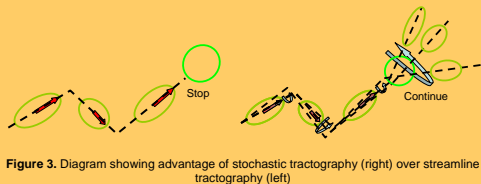


Figure 3. Diagram showing advantage of stochastic tractography (right) over streamline tractography (left)

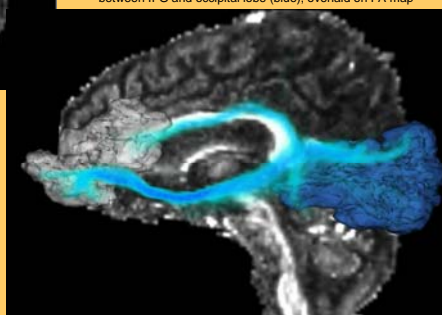


Figure 4b. (below) Connections extracted by stochastic tractography between IFG and occipital lobe (blue), overlaid on FA map

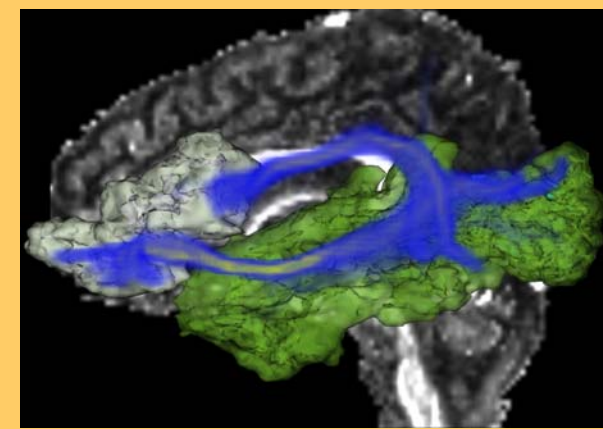


Figure 5. Combined connections extracted by stochastic tractography between IFG and STG/occipital cortices, overlaid on FA map

METHODS

Subjects

23 male chronic schizophrenics and 23 male normal controls, group matched for age, right-handedness, IQ, and parental socioeconomic status.

Data Acquisition

Magnetic Resonance Images (MRIs) were acquired on a 3.0 Tesla GE scanner. Structural MRIs were obtained with the following parameters: TR 7.48 ms, TE 3 ms, FOV 256 mm, 1 mm slice thickness, 176 axial slices. Diffusion Tensor MRIs were obtained with the following parameters: 51 directions, TR 17000 ms, TE 78 ms, FOV 24 cm, 144x144 encoding steps, 1.7 mm slice thickness, 85 axial slices.

Regions of Interest

Automatic Freesurfer (<http://surfer.nmr.mgh.harvard.edu>) segmentations were run on structural MRIs, from which the IFG, STG, and occipital lobe were extracted and measured (Figure 2).

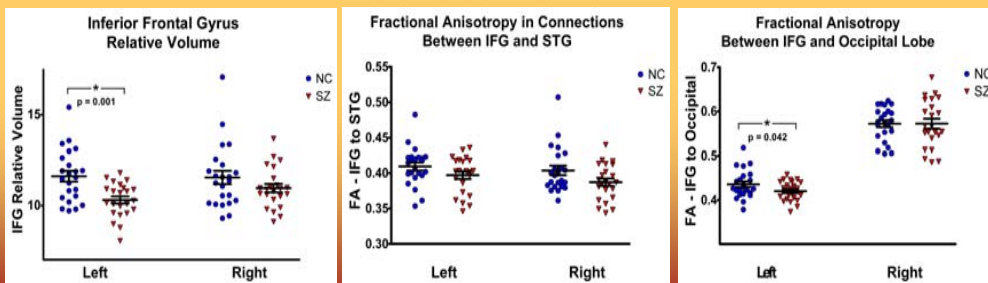
Non-linear co-registration of structural and DTI scans was then performed to convert the regions of interest (ROIs) to DTI space.

Stochastic Tractography

A new method of stochastic tractography (Figure 3) was employed to extract IFG-STG (arcuate) (Figure 4a) and IFG-occipital (IOFF) (Figure 4b) connections.

Mean Fractional Anisotropy (FA) along the two extracted fibers (Figure 5) was calculated and compared between groups.

RESULTS



DISCUSSION

The significant decrease in left IFG volume in schizophrenia patients indicates that portions of language-related cortices are affected in patients when compared to controls. By using our stochastic tractography method, we were able to model diffusion uncertainty which allowed us to track through regions of low anisotropy where streamline methods typically fail (Figure 3). The results demonstrate the ability of the stochastic tractography method to extract tracts through two distinct networks, the IFG-temporal and the IFG-occipital. Our significant finding in left IFG-occipital connections suggests decreased integrity of fiber tracts involved in language processing in schizophrenia patients when compared to healthy controls. Correlations between volume and connectivity, however, were not significant, indicating that volume loss and connectivity faults are two independent processes.

REFERENCES

Adams J, et al (1993): ERP abnormalities during semantic processing in schizophrenia. *Schizophrenia Res* 10(3):247-257.
 Crow TJ (1989): Nuclear schizophrenic symptoms as a window on the relationship between thought and speech. *Br J Psychiatry* 173:303-309.
 Ford JM, et al (2002): Reduced communication between frontal and temporal lobes during talking in schizophrenia. *Biol Psychiatry* 51(6):485-492.
 Duffau H, et al (2008): White matter functional connectivity as an additional landmark for dominant temporal lobectomy. *J Neurol Neurosurg Psychiatry* 79(5):462-466.
 Heckers S, et al (1998): Impaired recruitment of the hippocampus during conscious recollection in schizophrenia. *Nat Neurosci* 1(4):318-323.
 Kareken DA, Moberg PJ, Gair RC (1998): Proactive inhibition and semantic organization: relationship with verbal memory in patients with schizophrenia. *J Int Neuropsychol Soc* 2(6):486-493.
 Mandonnet E, et al (2007): Does the left inferior longitudinal fasciculus play a role in language? A brain stimulation study. *Brain* 130(Pt 3):623-629.
 Nestor PG, et al (1997): Aberrant semantic activation in schizophrenia: a neurophysiological study. *Am J Psychiatry* 154(5):640-646.
 Ragland JD, et al (2001): Effect of schizophrenia on frontotemporal activity during word encoding and recognition: a PET cerebral blood flow study. *Am J Psychiatry* 158(7):1114-1125.
 Saykin AJ, et al (1991): Neuropsychological function in schizophrenia. Selective impairment in memory and learning. *Arch Gen Psychiatry* 48(7):1218-1224.
 Saykin AJ, et al (1994): Neuropsychological deficits in neuroleptic naive patients with first-episode schizophrenia. *Arch Gen Psychiatry* 51(2):124-131.
 Yurgelun-Todd DA, et al (1996): Functional magnetic resonance imaging of schizophrenic patients and comparison subjects during word production. *Am J Psychiatry* 153(2):200-205.